Feasibility of Using Deep Learning Techniques to Assess Hepatic Fibrosis Directly from Magnetic Resonance Elastography Source Images

Marc-Michel Rohé[1], Estanislao Oubel[1], Marie-Lise Grisoni[1], Stephen Djedjos[2], Robert P. Myers[2], Rohit Loomba[3] and Michael S. Middleton[3]

(1) Median Technologies, Nice, France; (2) Gilead Sciences Inc., Foster City, USA; (3) University of California, San Diego, USA

BACKGROUND

- **Nonalcoholic steatohepatitis** (NASH) is a form of liver disease characterized by hepatic accumulation of fat, inflammation, and usually also fibrosis that may progress to cirrhosis [1].
- **Liver biopsy**, an invasive procedure, is the reference standard for assessing NASH disease activity and staging hepatic fibrosis.
- **Magnetic resonance elastography** (MRE) is a noninvasive liver imaging method that estimates liver stiffness as a surrogate of hepatic fibrosis [2,3,4].
- MRE liver stiffness values are to some extent dependent on the analysis software that is used, but accuracy can be low, especially for earlier stages of fibrosis.
- Recently, **deep learning (DL) methods** have shown impressive results in computer vision as a way to analyze images [5].

OBJECTIVES

- Our objective was to evaluate the use of a DL fully-convolutional neural network (CNN) [6] to discriminate advanced (F3-F4) from early (F1-F2) fibrosis in patients with biopsy-proven NASH and then to validate those results using a separate MRE source dataset.

MATERIAL

- **Centrally-read 2D MRE** was performed at baseline (BL), Week 12 and Week 24 (W24) in 67 subjects with NASH (NAS ≥5 and F2-F3 fibrosis) enrolled in a phase 2 trial of selonsertib (NCT02466516) [7].
- **Liver biopsies at BL and W24 were staged** for fibrosis using the NASH CRN classification by a central pathologist.
- We used MRE source images from **120/170 (70.6%) exams** and histologic hepatic fibrosis stages as **training examples**.
- Diagnostic performance was assessed in a validation cohort consisting **of the remaining 50/170 (29.4%) MRE exams**.

METHODS

- We developed a proprietary DL method (iBiopsy® DL) using a similar architecture as [5,6] to generate a fibrosis score map **(range: 0 to 1) which was hypothesized to correlate with histological fibrosis stage.**
- Our DL CNN model **(see figure attached)** is composed of **15 layers with a total of roughly 500,000 parameters** which were optimized on the training examples using an ADAM optimizer with a learning rate of 1e-3. Optimization took 3 hours on **a GTX 1080 Ti GPU.**
- A mean hepatic fibrosis score was computed by averaging values from this map **for a region of interest (ROI) manually defined within the liver.**

RESULTS

- iBiopsy® DL fibrosis scores correlated with conventionally-calculated MRE-stiffness **(Spearman r=0.756, p<0.001).**
- Validation cohort: the area under the ROC curve (AUROC) of iBiopsy® DL for the discrimination of F3-F4 vs. F1-F2 fibrosis was **0.834 (95% CI: 0.701, 0.937).**
- **AUROC of iBiopsy® DL was higher than that of MRE** (AUROC 0.802, 95% CI: 0.653, 0.919), but the difference was not statistically significant (p=0.58).
- Our iBiopsy® DL method, compared to MRE (resp. MRE) had a **sensitivity of 76% and specificity of 79% (resp. 68% and 90%)** at a cut-off value (computed using the closest top-left method) of 0.63 (resp. 4,4 kPa).

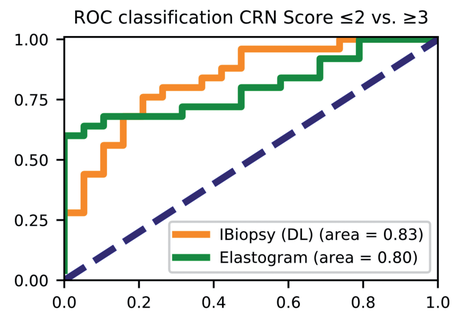

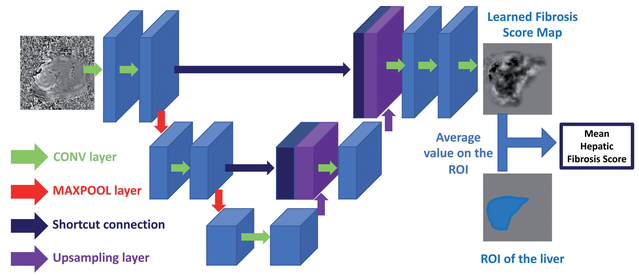

CONCLUSIONS

- Estimation of hepatic fibrosis severity directly from MRE source images is **feasible using CNNs.**
- **iBiopsy® DL** can learn the features in the images that correlate with hepatic fibrosis from training examples, potentially optimizing the amount of information extracted.
- Validation in a larger cohort is needed to confirm **statistical significance of results** compared toconventional MRE liver stiffness quantification.

REFERENCES

[1] Vernon G. *et al.*, Aliment Pharmacol Ther. 2011. 34(3): 274-285.
[2] Muthupillai R. *et al.*, Science. 1995. 269(5232): 1854-1857.
[3] Manduca A. *et al.*, Med Image Anal. 2001. 5: 237-254.
[4] Loomba R. *et al.*, Hepatology. 2014. 60: 1920-1928.
[5] Krizhevsky A. *et al.*, NIPS. 2012.
[6] Long J. *et al.*, ICVPR. 2015.
[7] Loomba R. *et al.*, Hepatology. 2018. 67(2): 549-559.

ACKNOWLEDGEMENTS

We acknowledge Corinne Ramos for her support in this work. We extend our thanks to the patients and their families. These studies were funded by Gilead Sciences, Inc.

There is no conflict of interest

© 2018 Median Technologies