

## Medical imaging in oncology review

### Overview

Medical imaging allows clinicians to identify the exact anatomical location and extent of disease. Medical imaging also provides clinicians information on tumor response to therapies. The noninvasive nature of imaging enables continual assessment of a patient's disease state and response to treatment with minimal discomfort to the patient. The resultant digital images facilitate quantitative measuring of endpoints, which are critical for reporting or comparing results within or across clinical trials.

#### Imaging biomarkers vs endpoints:

A biomarker is a biological characteristic that is objectively measured and evaluated as an indicator of normal or pathological processes. An imaging biomarker is a biological characteristic that is detectable on an image.

- Imaging biomarkers can be anatomical or functional.
- Imaging biomarkers can be qualitative i.e., descriptive – “a nodule is present in the lung” or quantitative i.e., objectively measured parameter – “the longest diameter of the nodule decreased by 5mm after treatment as compared with its size before treatment.”

Endpoints are the outcomes of a trial used to determine if a therapy is safe and effective. Once a patient reaches an endpoint, he/she is generally removed from the trial.

- Clinical endpoints are hard endpoints such as patient death.
- Surrogate endpoints are substitutes for a clinical endpoint and correlate with clinical benefit.
- An imaging biomarker can become a surrogate endpoint after going through a rigorous qualification and validation process.

#### DICOM image format

Digital Imaging and Communications in Medicine (DICOM) is the international standard image format for clinical data.

- DICOM is an information technology standard that allows devices that produce, display, send, store, retrieve, or print imaging data to work together and exchange information.
- DICOM allows users to produce, manage, and distribute images regardless of equipment vendor or location.
- DICOM ensures that all images can be uploaded, transferred, and read, independent of the model or manufacturer of the imaging equipment used to acquire the images.

#### Image orientation

There are three primary orientations in which an image can be recorded:

##### **Axial**

*Divides the body into superior and inferior positions (head and feet); also called transverse*

##### **Coronal**

*Divides the body into dorsal and ventral (front and back)*

##### **Sagittal**

*Divides the body into left and right sides*

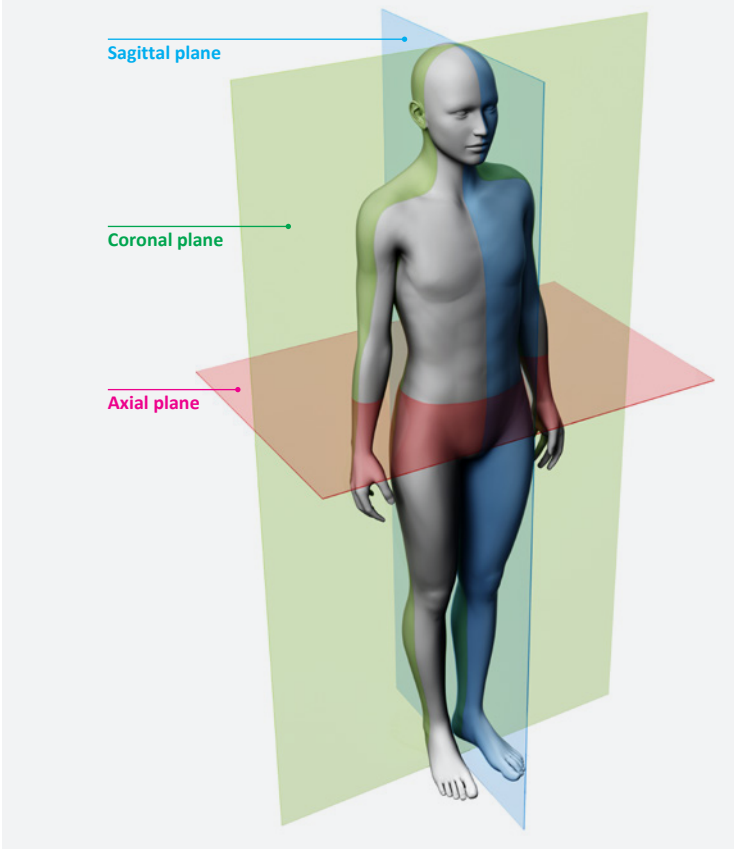


Image modalities

X-Ray

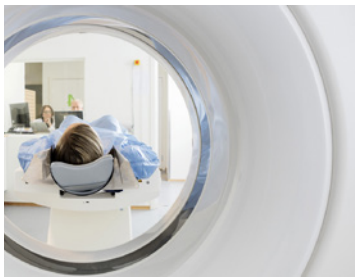
- Produces 2-dimensional images; best for imaging the skeleton.
- An x-ray machine sends out a beam of x-rays at the patient that are captured on the other side by x-ray film or a digital detector. The x-rays are either scattered or passed through the body depending on the density of the object.

Advantages

Low cost; widely available; portable

Disadvantages

Exposes patient to radiation; produces 2D images; limited color spectrum (black/white)



Median is the right imaging solution for your oncology clinical trials. By bringing together image specialists, superior technology to automate and standardize image management and expert data & project management teams, we provide you with the most meaningful data so you can make better and quicker decisions about your cancer therapy. Median Technologies is a full service global imaging clinical research organization with experience in Phase I - III oncology trials.

Computer Tomography (CT)

Uses x-rays to produce a 3-dimensional image in all three orientations: axial, coronal, sagittal.

Tomography

An imaging method that scans the body in sections. The width of each section is referred to as the slice thickness.

CT, MRI, and PET are all tomographic methods.

- Most widely used imaging modality: generates anatomical information and is often used to assess lesion size in oncology.
- X-rays are aimed at the patient and are attenuated (scattered) based on the density of the tissue. A new image is taken every few millimeters.
- The less dense the material (e.g., fat), the more black it appears on the image; the more dense the material (e.g., bone) the lighter it appears; creates a black-white color gradient.
- Modern CT scanners contain many (up to 256) x-ray emitters and detectors to produce ultra-fast image acquisition times.
- CT can also involve the use of contrast agents: injected or swallowed liquids with a specific density that are used to highlight a particular organ, vascular structure, or anatomical region.

Advantages

Produces cross-sectional view; use of contrast agents; rapid acquisition

Disadvantages

Cost; radiation

Magnetic Resonance Imaging (MRI)

Standard MRI: anatomical imaging

- Produces 3-dimensional images using a magnetic field and radio waves: does not use radiation.
- Magnetic field strength measured in Tesla (T), typically ranging from 1.5 to 3 Tesla.
- Produces images based on the spin of hydrogen nuclei (such as those found in water).

Advanced MRI: functional imaging

- Dynamic contrast-enhanced MRI: Contrast agent (e.g., gadolinium) is added to enhance anatomical structures: blood vessels (tumor angiogenesis in prostate cancer); brain tumors.
- Diffusion-weighted imaging (DWI): measures diffusion of water in tissues; useful for assessing ischemia and vascular changes in tumors related to malignancy or treatment response.

Advantages

Lack of radiation can be better for patients; superior to CT for visualizing soft tissue (for example, brain tumors)

Disadvantages

More costly and time consuming than CT; patients can become claustrophobic in the magnetic tube; ferromagnetic objects such as some pacemakers can be dislodged

Positron Emission Tomography (PET)

Nuclear imaging modality based on the use of radiolabeled tracers and tracking their distribution throughout the body.

- Radioactive isotope is chemically attached to a biologically important molecule.
- The radiolabeled tracer releases energy (positrons) as it decays, which is detected and recorded to create an image.
- Radioactive decay lasts for a specific and defined amount of time (i.e. half life). The half life of each radioisotope is unique to that isotope.
- Produces 2D and 3D images; example of functional imaging.
- Metabolic changes (using FDG-PET) can be detected earlier than anatomical changes such as an increase in tumor size.
- PET has limited spatial resolution, so it is commonly combined with CT or MRI (PET/CT or PET/MRI) to obtain functional and anatomical data in a single imaging session.

Advantages

Metabolic changes can be detected earlier than anatomical changes; can provide simultaneous functional and anatomic data when combined with CT; easier detection of early-stage tumors

Disadvantages

Low spatial resolution when not combined with CT; radiation exposure; potential allergy or adverse response to radiotracer; high cost